

From:
PAUL C. BEAVER
To C. C. Bass
12 Mar 62
Paul C. Beaver
Compliments
of the author

15965

Habitat of Endameba buccalis in Lesions of Periodontoclasia.*

CHARLES C. BASS.

From the School of Medicine, Tulane University of Louisiana, New Orleans, La.

Many years ago Johns and I¹ showed that *Endameba buccalis* are most numerous at the very bottom of the pyorrhoea pocket. Later Kofoid² substantiated, and extended the application of this observation.

Studies of amebae in periodontoclasia have been based largely upon material taken from the lesions around and between teeth *in situ*. Although dental literature contains large numbers of illustrations of sections of teeth, including the periodontal tissues in all stages of periodontoclasia, the amebae present usually have been overlooked. Probably this has resulted from the fact that they are located within the bacterial film on the tooth and are not easily recognized in sections prepared in the usual way. Kofoid and Hinshaw³ reported the distribution of the amebae found

at different levels in relation to the calculus in sections of two incisors removed at biopsy.

More recently, employing an entirely different method, I have been able to ascertain, more accurately, the location and habitat of the parasite in these lesions. The method consists essentially of microscopic study of material removed, under the dissecting microscope, with delicate micro-instruments, from different locations on extracted teeth which have been stained to facilitate identification of the structures and material present.

Elsewhere I⁴ have described a previously unrecognized demonstrable line on extracted teeth which indicates the location of the outer border of the epithelial attachment. It is called the "zone of disintegrating epithelial-attachment cuticle" or zdeac. This line not only indicates the location of the outer border of the epithelial attachment, but it also accurately indicates the location, on the tooth, of the very bottom of the periodontoclasia lesion. With the zdeac as a guide, small particles of the soft bacterial film material can be picked from any selected areas and

* Studies promoted by facilities to which I have had access at the School of Medicine, Tulane University of Louisiana, and by aid for equipment and supplies provided by the University.

¹ Bass, C. C., and Johns, F. M., *J. A. M. A.*, 1915, 64, 553.

² Kofoid, C. A., *J. Paras.*, 1929, 15, 151.

³ Kofoid, C. A., and Hinshaw, H. C., *J. D. Res.*, 1929, 8, 446.

⁴ Bass, C. C., *J. D. Res.*, 1946, 25, 401.

locations at and near the bottom of the lesion.

Technic. The equipment and technical procedures previously described⁴ are required. Safranin (0.5% in water) is satisfactory for staining tooth specimens for the present purpose. Immerse the formalin preserved specimen in the stain 3 to 5 minutes or longer. Wash well in water and examine under the dissecting microscope. The zdeac is not sharply shown on specimens stained with safranin but it can be recognized satisfactorily by one who has previously familiarized himself with this important landmark.

For removal of particles of material for examination under higher magnifications, a suitable micrurgic blade is required. This is made⁴ from a very fine needle, the point of which is ground to a thin blade or chisel shape, not more than 0.25 mm wide.

With the specimen in the field of the dissecting microscope and a good light focussed upon it from above, small particles are picked from the thin edge of the soft stained material extending down to, and sometimes overlapping, the outer border of the zdeac. One or more such selected particles are transferred to a droplet of 50% glycerine on a slide and there teased apart, if desired, with the aid of 2 very fine pointed needles. A $\frac{1}{4}$ size coverglass is put on but not pressed down too hard. The mounted specimen is now ready for examination.

By proper adjustment of the light, different levels around the thin edge of particles and for some distance inward, can be focussed well enough to recognize the amebae and the filaments and branches of the leptotrichia among which they are imbedded.†

The Periodontoclasia Lesion. The lesion of periodontoclasia consists of a pocket or space ("pyorrhoea pocket") at various locations

† The amebae are imbedded in a mass of bacterial material. This must be stained lightly with a weak stain to permit focussing upon them through the mass.

These amebae have not been generally observed in paraffin or celloidin sections of teeth and parodontal tissues. Perhaps this explains, to some extent, why the habitat of this widely distributed parasite has not been generally recognized in such material heretofore.

about the tooth, and may extend all way or only part way around it. There is much variation in the depth of lesions around different teeth, and that of the lesions at different locations around the same tooth.

On one side of the lesion there is an inflamed suppurating surface of epithelial tissue extending from the gingival margin to the bottom of the lesion. On the opposite side is the tooth which is covered with more or less hard calculus. Attached to the calculus and to the tooth near it, not yet covered with calculus, there is a pad of soft bacterial material consisting of a compact mass, of variable thickness, of stems and filaments extending outward towards the space and downward towards the very bottom of the lesion. This latter has been noted recently by Box,⁵ not, however, with any reference to amebae present.

The outer part of the pad attached to the tooth consists largely of radiating filaments which protrude at the surface as a thick-set carpet-like pile of growing, branching and fruiting stems. It is possible that the compact portion of the bacterial pad attached to the tooth may consist of several different kinds of organisms of this type. However, the fruiting heads on the surface and the stems that can be focussed deeper in conform, in most instances, to *Leptothrix falciformis*. This organism was first described in material from around teeth by Buest⁶ and given the name *L. falciformis*, because of the scythe- or blade-shaped conidia produced on the fruiting branches. These conidia or spore bearing curved to straight rods of varying size radiate, at an angle, from the central stalk, which is also surrounded by a large amount of jelly-like material in which the falciforms are imbedded.

Association of the Amebae with Leptotrichia and their Distribution. Intimate association of *E. buccalis* with filamentous bacterial material has been observed.^{3,7,8} Good-

⁵ Box, H. K., *J. Canadian D. A.*, 1947, **13**, 3.

⁶ Buest, Theo. Von, *Dent. Cos.*, 1908, **50**, 594.

⁷ Barrett, M. T., *Dent. Cos.*, 1914, **56**, 948.

⁸ Goodrich, H. P., and Mosely, M., *J. Roy. Mic. Soc.*, 1916, Dec., 513.

all way or
 re is much
 around dif-
 fusions at dif-
 ferent tooth.
 There is an in-
 thelial tissue
 margin to the
 opposite side
 with more or
 less the calculus
 covered with
 bacterial ma-
 ss, of vari-
 filaments ex-
 ce and down-
 of the lesion.
 ntly by Box,⁵
 ce to amebae

ttached to the
 ing filaments
 as a thick-set
 branching and
 that the com-
 ad attached to
 veral different
 pe. However,
 rface and the
 deeper in con-
Leptothrix falci-
 first described in
 by Buest⁶ and
 because of the
 ia produced on
 conidia or spore
 rods of varying
 om the central
 ded by a large
 l in which the

with *Leptotri-*
 Intimate asso-
 filamentous bac-
 rved.^{3,7,8} Good-

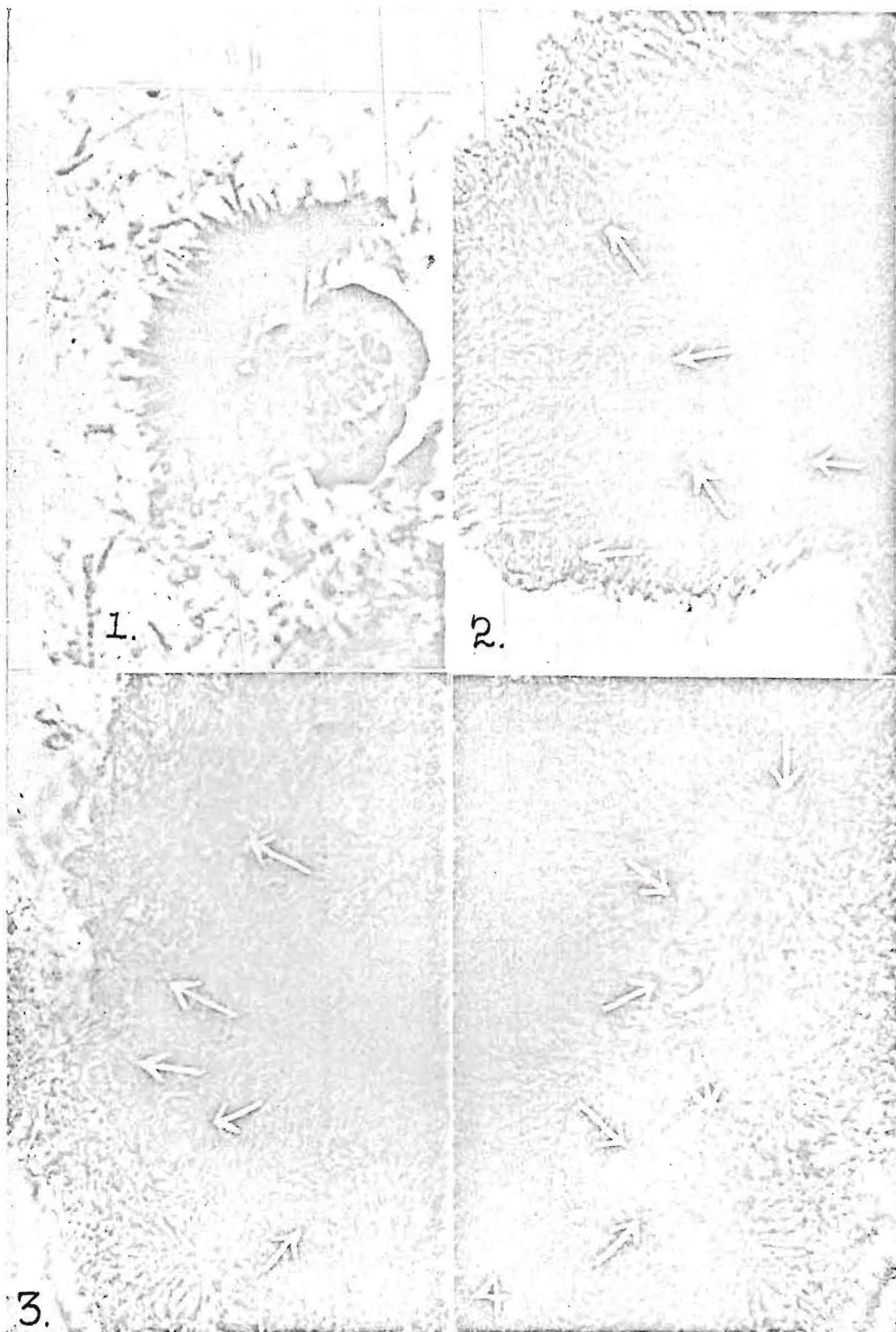


Fig. 1. *E. buccalis* mounted, for comparison, by the side of an isolated fruiting stem of *L. falciiformis*. $\times 1200$.
 Fig. 2. Outer edge of leptothrix bed; fruiting head covered with spirochetes: arrows point to ameba at edge and others, not sharply focussed, deeper in. $\times 810$.
 Fig. 3. Leptothrix bed; arrows point to amebae, partially focussed. $\times 810$.
 Fig. 4. Deep leptothrix bed; arrows point to imbedded amebae. $\times 810$.

A., 1947, **13**, 3.
 , 1908, **50**, 594.
 1914, **56**, 948.
 M., *J. Roy. Mic.*

Entameba buccalis, HABITAT IN PERIODONTOCLASIA

rich and Mosely⁸ found that these amebae (*Entameba gingivalis*) are in greatest numbers on the under side of the tartar ridge. They claim that the parasites do not burrow into the tissues of the gum but often between the terminal branches of the leptotrichia which are found in abundance in the pyorrhoea lesion.

The space between the leptotrichial bed on the one side and the inflamed epithelial wall on the other, contains inflammatory tissue exudate, large numbers of bacteria of many varieties, spirochetes and usually some amebae which have come out from their bed to their feeding ground where there are an abundance of pus cells upon which they feed. After feeding the parasite usually withdraws into the leptotrix bed for safety and protection. Individuals that venture too far away from the bed into the open space are unable to return and are swept out with the pus, especially when it is squeezed out by pressure upon the tooth in chewing, biting, etc.

The parasites are found scattered among the branches and fruiting heads (Fig. 1) of the leptotrix bed. The individual not only burrows between the different elements—stems, filaments, falciforms—making up the outer surface, but apparently they also burrow about in the abundant jelly-like material imbedding these elements (Fig. 2, 3, 4). In studying several hundred such specimens as suggested here, I have often observed several amebae clustered about a leptotrix stalk and especially in the fork where a large stalk apparently divides into 2 smaller ones. For the most part, however, they are found separate and not in direct contact with each other.

Summary. A simple method is given, of collecting material from the area on extracted teeth, which is inhabited by *E. buccalis*.

The habitat of *E. buccalis* is the outer part of the filamentous bacterial film on the tooth, within the periodontoclasia lesion. There they are protected and live, grow and multiply among the strands and fruiting heads of leptotrichia, principally *L. falciformis*.