

THE RELATION OF THE INNER
BORDER OF BACTERIAL FILM
ON THE TOOTH WITHIN THE
GINGIVAL CREVICE TO THE
ZONE OF DISINTEGRATING
EPITHELIAL ATTACHMENT
CUTICLE

CHARLES C. BASS, M.D.
New Orleans, La.

From the School of Medicine, Tulane University
of Louisiana

Reprinted from
ORAL SURGERY, ORAL MEDICINE, AND
ORAL PATHOLOGY
St. Louis

Vol. 2, No. 12, Pages 1580-1590, December,
1949

(Printed in the U. S. A.)

**THE RELATION OF THE INNER BORDER OF BACTERIAL FILM ON
THE TOOTH WITHIN THE GINGIVAL CREVICE TO THE
ZONE OF DISINTEGRATING EPITHELIAL
ATTACHMENT CUTICLE***

CHARLES C. BASS, M.D., NEW ORLEANS, LA.

THE zone of disintegrating epithelial attachment cuticle (zdeac) is a useful landmark which can be demonstrated on extracted tooth specimens by appropriate technique.¹ It accurately indicates the location, before the tooth was extracted, of the outer border of the epithelial attachment. As the location of the epithelial attachment moves apexward in the course of the disease process, periodontoclasia, the location of this demonstrable line (the zdeac) changes correspondingly apexward from its normal location high on the anatomical crown.²

This line consists of a narrow band of variable width, of epithelial attachment cuticle, from which the cells of the epithelial attachment have been removed or destroyed.¹ This strip of epithelial attachment cuticle which is not covered and therefore is not protected by epithelium is thus exposed to the encroachment of the bacterial film adhering to the surface of the tooth within the gingival crevice. It is also exposed to the effect of the microflora inhabiting the narrow space existing between the more or less permanent or constant film attached to the tooth and the inflamed gingival side of the crevice (sulcus or pyorrhea pocket). To what extent the disintegration of this exposed (not protected by epithelial cells) strip or zone of epithelial attachment cuticle is caused by the attached bacterial film, or by the microflora of the space (crevice) between the film and the crevicular epithelial surface, is not known at the present time. Probably it is a very complex process influenced to variable extent by both the attached bacterial film and the free (not attached) flora sandwiched in between the film and the crevicular epithelium. The purpose of this paper is to direct attention to the constant close relation of the inner border of the attached film pad on the tooth to the zdeac.

Material and Methods

Extracted tooth specimens preserved in formalin (preferably 2.5 per cent following the original fixation in any strength from 2.5 per cent to 10 per cent) are satisfactory. Specimens should not be scraped, scrubbed, washed,

From the School of Medicine, Tulane University of Louisiana.

*Studies promoted by facilities to which the author has had access at the School of Medicine, Tulane University of Louisiana, and by aid for equipment and supplies provided by the University.

or allowed to dry before fixation. On most specimens one can usually find areas where more or less receding of the outer border of the epithelial attachment and corresponding receding of the zdeac has occurred. On many specimens the receding is already well advanced. Specimens from adults are usually more satisfactory for the present purpose. In general the zdeac is located farther toward the apex on specimens from older than from younger subjects.

The equipment and technical methods previously described¹ for demonstrating the zdeac are necessary for the present purpose. In addition to the 0.35 mm. micrurgic blade previously suggested for removing and manipulating small pieces of cuticle and other material, a similar chisel- or spatula-shaped blade, not more than 0.15 to 0.20 mm. wide, is needed for accurately picking very small particles of material from the inner border of the bacterial film.

The tooth specimen is stained for about one minute in crystal violet solution (0.5 per cent in water) and then gently washed in water. It is now ready for examination under the dissecting microscope. Good incident lighting is necessary.

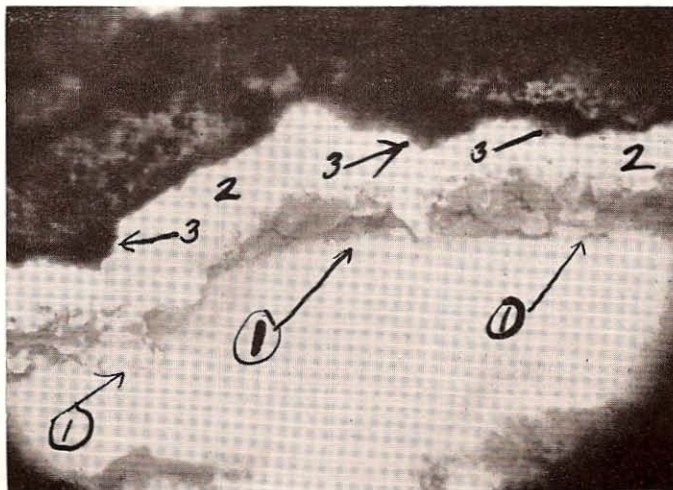


Fig. 1.—Specimen prepared especially to demonstrate the disintegration that has taken place on the occlusalward side of the zdeac (1). Specimen brushed off after staining. This removes soft bacterial film and also loose particles of disintegrating cuticle, leaving a wider clear space (2) between what remains of the zone and the calculus above. Some bacterial material (3) at the lower edge of the calculus was protected and therefore not removed by the brushing.

Observations

On favorable specimens the purple-stained zdeac can be recognized satisfactorily at some place or places on the specimen. Often it can be traced all the way around the tooth. Usually there is more or less distortion, at places, of the soft material on the tooth, produced by the manipulations of extraction. Both the zdeac and the bacterial film may have been disturbed or scraped away at any particular location, and this must be kept in mind in interpreting conditions found there. However, it is usually possible to find locations on

most specimens at which neither the zdeac nor the inner border of the bacterial film has been disturbed.

The disintegration (breaking up) has progressed for a longer period of time at the outer border of the zdeac than at the deeper apexward border.

Fig. 2.

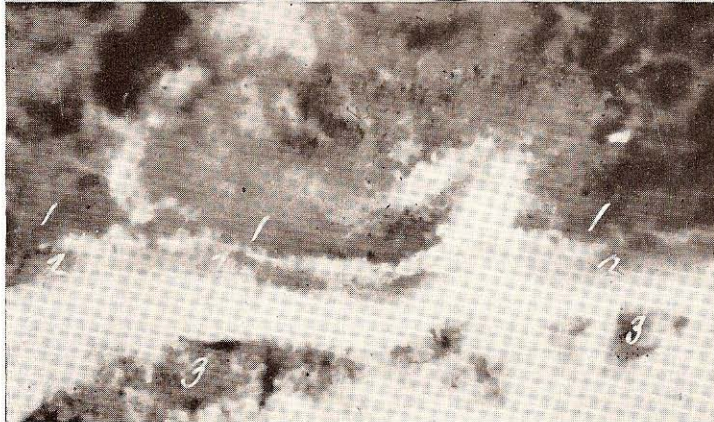



Fig. 3.

Fig. 2.—Area showing inner border of attached bacterial film (1) approaching the zdeac (2) all along. Remnants of epithelial attachment were mostly torn away, and at only one place (3) came right to the zdeac.

Fig. 3.—Area showing inner border of attached bacterial film (1) extending right down to zdeac (2). Remnants of epithelial attachment (3) displaced away from zdeac by manipulations of extraction.

Therefore, it is more advanced on that side of the zone. Loose or partially detached pieces of cuticle can be found there. Debris from the disintegrating cuticle and the irregular outline (Fig. 1), resulting from breaking off of loosened particles, makes it difficult to identify accurately the exact outer border of the zone at a given place. Moreover, the usual slight to considerable extension of the inner border of the bacterial film over the outer border of the zone tends to obscure it.

The Bacterial Film

The bacterial film on the tooth is heavily stained by the one-minute exposure suggested previously. Wherever the film is very thick, the stain does not have time to soak into and stain the deeper part next to the tooth. However, the surface of the film pad, including the inner border of it at the zdeac,

Fig. 4.

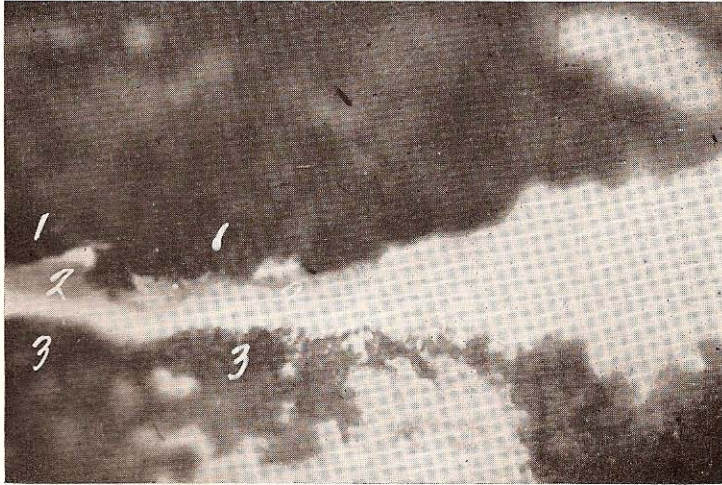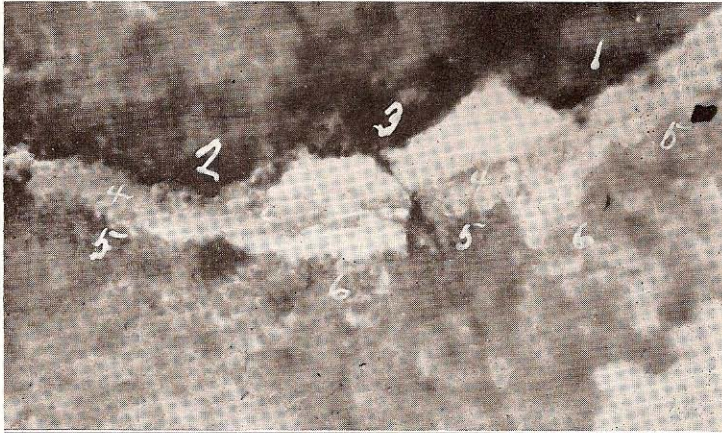


Fig. 5.

Fig. 4.—Area showing inner border of attached bacterial film extending to (1), slightly overlapping (2), and scraped back from (3) the zdeac (4). Remnants of epithelial attachment extend right to (5) the apexward side of zdeac; torn back at 6.

Fig. 5.—Area showing, at left, inner border of the attached bacterial film (1) extending right to the occlusalward border of the zdeac (2). Remnants of the epithelial attachment extend nearly to the apexward side of the zdeac.

is well stained. At favorable places it can be seen that this film always extends right down to (Figs. 2 and 3) and often slightly overlaps (Figs. 4 and 5) the occlusalward border of the zdeac.

The characteristics and composition of this material can be observed

Fig. 6.

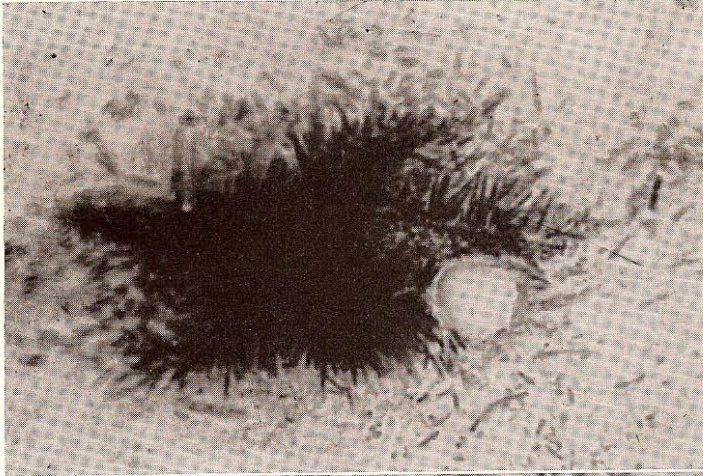


Fig. 7.

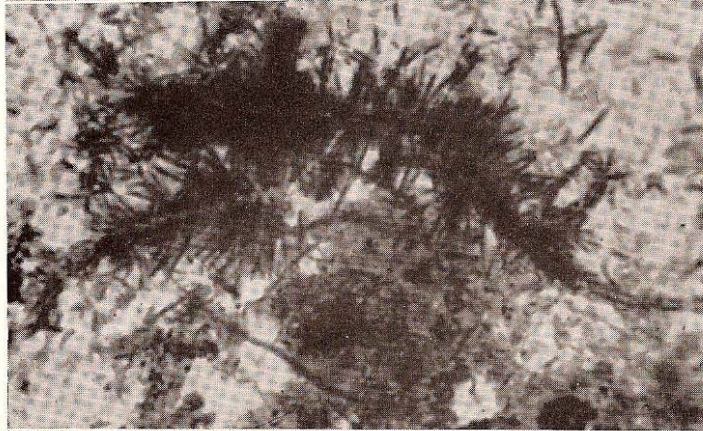


Fig. 8.

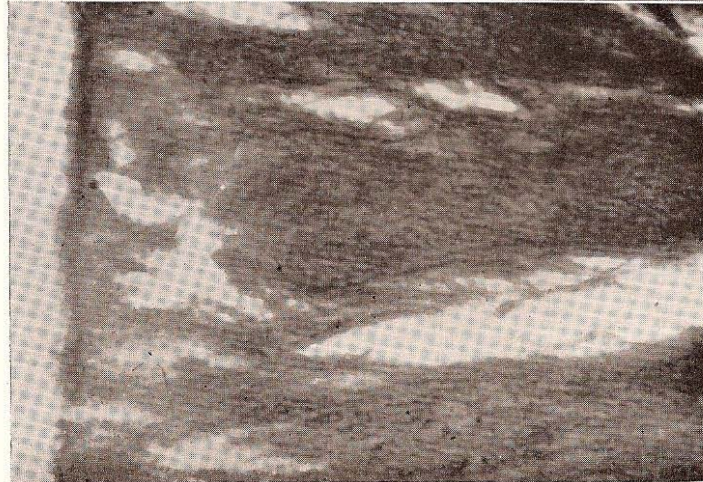

Fig. 6.—Portion of fruiting heads of *L. falciformis* teased apart, and showing, at right, stem with falciforms detached and also others nearly mature still attached.

Fig. 7.—Portions of fruiting heads of *L. falciformis* teased apart, showing stems and attached immature falciforms.

Fig. 8.—Highly magnified field on section through bacterial film pad which was originally attached (at left) to the tooth within the gingival crevice. Parallel filaments, slightly pulled apart, compose this deeper part of the pad.

best by picking a small particle from the inner border of the bacterial film and examining it under appropriate magnification. For most purposes it is only necessary to tease apart the particle in a small droplet of 50 per cent glycerine on a slide, put on a quarter-sized coverglass, and examine. Very fine-pointed teasing needles are required. Such manipulations are best carried out under the dissecting microscope. Magnification of twelve to fifteen times is desirable for teasing out and preparing such material on the slide. Also, this material can be teased out in water on a slide, allowed to dry, and restained as desired.

Another good method for studying the nature of the inner border of the bacterial film and its relation to the zdeac is to select a favorable area where the zone is still on the enamel, dip in acid (10 per cent Hcl.) for a moment, remove a small piece of cuticle which includes the objects of interest, and restain this.

Sections made through appropriate areas on decalcified (10 per cent Hcl.) tooth specimens are also helpful in studying the bacterial film attached to cementum within the gingival crevice.

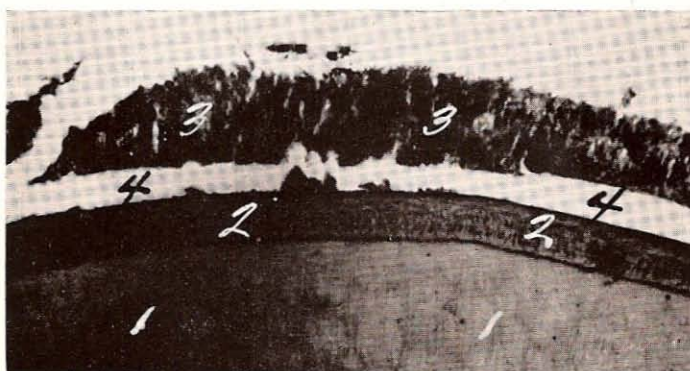


Fig. 9.—Cross section of root through attached bacterial film pad within gingival crevice, showing parallel arrangement and outward extension of filaments of which it is composed. Dentine (1), cementum (2), bacterial film (3), space resulting from detachment in making preparation (4).

Material removed from the inner (apexward) border of the film pad approaching and overlapping the occlusalward border of the zdeac is found to consist mainly of parallel-arranged long rods and filaments. Growing and fruiting ends of these are usually found in preparations which include the surface and the extreme apexward feathery edge of the pad. This form was described by Beust³ in 1908 and designated by him as *Leptothrix falciformis* (Figs. 6 and 7). In 1929 he again directed attention⁴ to this organism in material from about the teeth, and pointed to the association of it with spirochetes.

From time to time, others^{5, 6, 7, 8, 9, 10, 11} have recognized what seems to be this same organism. Box^{9, 10} especially has shown convincingly, with photomicrographs* of sections, that some of the fruiting heads tend to grow down-

*Reference 9, Figs. 1 and 2, reference 10, Fig. 4.

ward toward the very bottom of the pocket. Studies of large numbers of suitable preparations, as herein suggested, show that the film pad near the zdeac consists largely of parallel rods and filaments (Figs. 8 and 9), one end attached to the tooth and the other consisting mostly of growing ends and fruiting heads extending outward and downward into the open space of the gingival crevice (Figs. 10, 11, 12, 13, and 14).

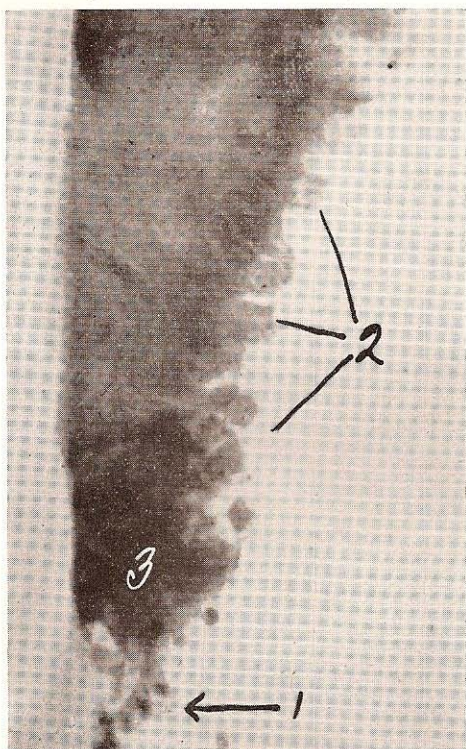


Fig. 10.—Section through bacterial film pad (separated from tooth) at the very bottom of periodontoclasia lesion, indicating how filaments extend outward from the tooth. Some pus cells (1) at the bottom and some ameba (*Endamoeba buccalis*) (2) among the leptothrix heads and stems. Material picked from area (3) which was originally over the zdeac would consist of almost pure spirochetes.

While this paper refers especially to attached bacterial film on the tooth at the bottom of the periodontal lesion, attention may be called to the great abundance and preponderance of spirochetes* in the narrow space between the attached film pad and the epithelial cell wall of the pocket. Spirochetes are so numerous at the very bottom of this space overlying the zdeac (Fig. 15) until, on favorable specimens and with good technique, one can pick material from over the zone, which consists of practically pure spirochetes (Fig. 16). The great abundance of spirochetes found upon and about the fruiting heads of leptothrix film is indicated in photomicrographs† published previously by me.¹²

*The term spirochete is used here in its broader sense to indicate spiral, corkscrew-shaped organisms.

†Reference 12, Figs. 2 and 3.

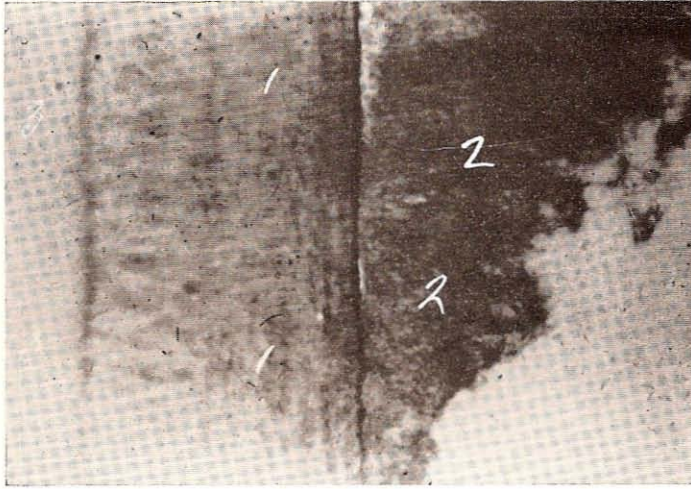


Fig. 11.—Section through bacterial film attached to cementum (1) at the very bottom of the periodontoclasia lesion, showing extension outward (2) of the filaments composing the pad. Dentine (3).

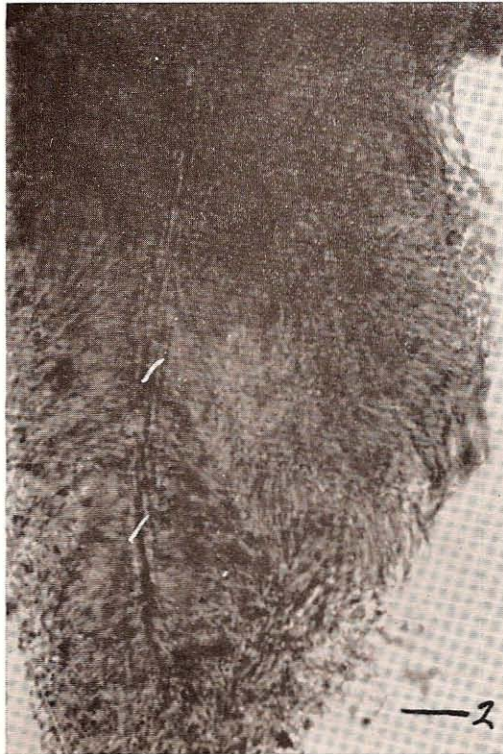

Fig. 12.—Material picked from the inner border of the attached bacterial film overlying the occlusalward border of the zideac. The focus is on the filaments (1) making up the stem of one of the falciform-bearing "thread form" fungi. Spirochetes around edge at some places (2).

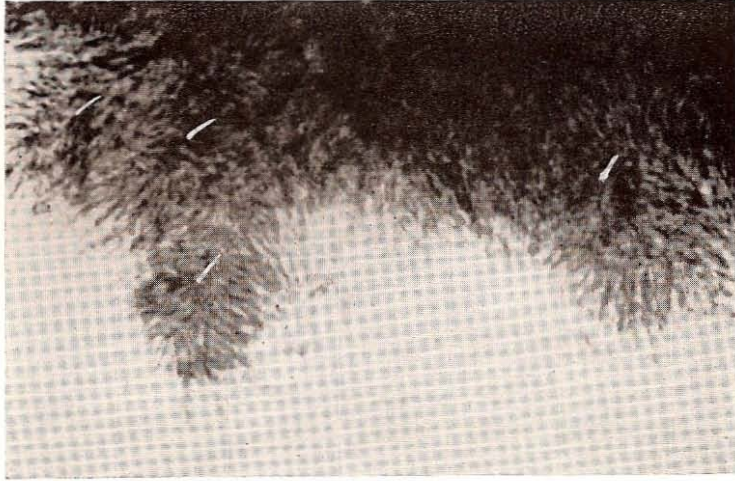


Fig. 13.—Material picked from the fringe of the inner border of attached bacterial film at the occlusalward border of the zideac, showing fruiting falciform heads (1) with spirochetes around the edge.

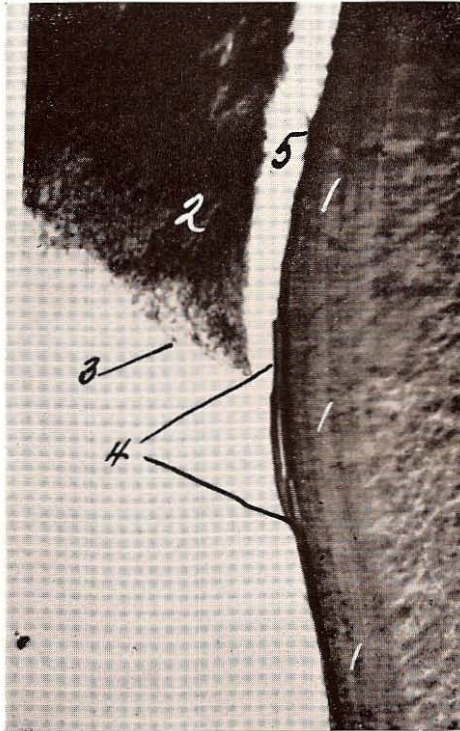


Fig. 14.—Section through attached bacterial film on cementum (1) within periodontoclasia lesion. Filaments of pad (2) extend outward and downward; spirochetes (3) at surface slightly overlapping zideac (4). Space (5) resulting from detachment in making preparation.

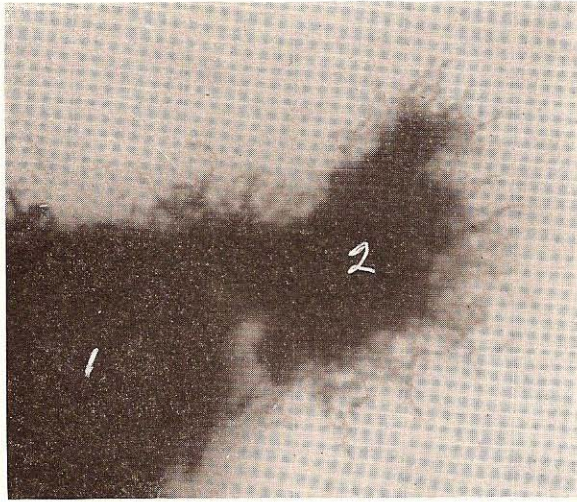


Fig. 15.—Material picked from over the occlusalward side of zdeac. Bacterial mass (1) at left and mass of almost pure spirochetes (2) attached to it.

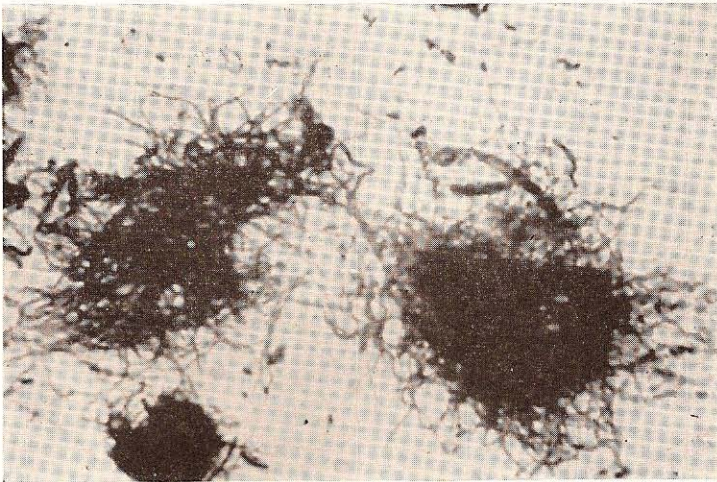


Fig. 16.—Almost pure spirochetes picked from over the zdeac just beyond the inner border of the attached bacterial film.

Summary

The inner (apexward) border of the bacterial film on the tooth within the gingival crevice extends right to and usually overlaps the outer (occlusalward) border of the zdeac.

The attached bacterial film consists of a pack of more or less parallel long rods and filaments, one end attached to the tooth and the other extending outward (from the tooth) into the narrow space between this film and the crevicular epithelium.

There is a great abundance of spirochetal organisms closely associated with the growing ends and fruiting heads in this space, especially the space immediately over the zdeac.

References

1. Bass, C. C.: A Demonstrable Line on Extracted Teeth Indicating the Location of the Outer Border of the Epithelial Attachment, *J. D. Res.* 25: 401, 1946.
2. Bass, C. C., and Fullmer, H. M.: The Location of the Zone of Disintegrating Epithelial Attachment Cuticle in Relation to the Cemento-Enamel Junction and to the Outer Border of the Periodontal Fibers on Some Tooth Specimens, *J. D. Res.* 27: 623, 1948.
3. Beust, Theo.: A Contribution to the Morphology of the Microorganisms of the Mouth, *Dental Cosmos* 50: 594, 1908.
4. Beust, Theo.: Spirochetes and Fusiform Bacilli of the Mouth, *J. Am. Dent. A.* 16: 1415, 1929. (See also *J. Am. Dent. A.* 16: 714.)
5. Goodrich, H. P., and Mosely, M. J.: Certain Parasites of the Mouth in Cases of Pyorrhoea, *J. Roy. Micr. Soc.* 61: 513, 1916.
6. Aisenberg, M. S.: Morphologic Studies of Microorganisms of Fusiform Type, *Dental Cosmos* 75: 546, 1933.
7. Dean, R. D., and Dean, M. T.: Cultural Observations on Fusospirochetal Infections, *J. D. Res.* 11: 759, 1931.
8. Tunnicliff, R.: Fusiform Organisms in the Mouth, *J. D. Res.* 17: 53, 1938.
9. Box, H. K.: Can Specific Infective Factors Operate to Deepen a Pocket? *J. Canadian D. A.* 10: 427, 1944.
10. Box, H. K.: New Aspects of Periodontal Research, *J. Canadian D. A.* 13: 3, 1947.
11. Cobe, H. M.: Vincents Infection: Experimental Reproduction of Lesions and the Role of Streptococci, *J. Am. Dent. A.* 37: 317, 1948.
12. Bass, C. C.: Habitat of *Endameba Buccalis* in Lesions of Periodontoclasia, *Proc. Soc. Exper. Biol. & Med.* 66: 9, 1947.